

available at www.sciencedirect.com
journal homepage: www.europeanurology.com



Surgery in Motion

Operative Details and Oncological and Functional Outcome of Robotic-Assisted Laparoscopic Radical Prostatectomy: 400 Cases with a Minimum of 12 Months Follow-up

Declan G. Murphy^{*}, Michael Kerger, Helen Crowe, Justin S. Peters, Anthony J. Costello

Department of Urology, Epworth Hospital, Richmond, & Royal Melbourne Hospital, Australia

Article info

Article history:

Accepted December 25, 2008

Published online ahead of
print on January 9, 2009

Keywords:

da Vinci
Laparoscopic
Prostate cancer
Radical prostatectomy
Robotic
Technique

Please visit
www.europeanurology.com
and www.urosource.com to
view the accompanying video.

Abstract

Background: Robotic-assisted laparoscopic radical prostatectomy (RALP) using the da Vinci[®] surgical system (Intuitive Surgical, Sunnyvale, CA) is increasingly used for the management of localised prostate cancer.

Objective: We report the operative details and short-term oncological and functional outcome of the first 400 RALPs performed at our unit.

Design, setting and participants: From December 2003 to August 2006, 400 consecutive patients underwent RALP at our institution. A prospective database was established to record the relevant details of all RALP cases.

Surgical procedure: A six port transperitoneal approach using a 4-arm da Vinci[®] system was used to perform RALP. This database was reviewed to establish the operative details and oncological and functional outcome of all patients with a minimum of 12 months follow-up.

Measurements: Perioperative characteristics and outcomes are reported. Functional outcome was assessed using continence and erectile function questionnaires. Biochemical recurrence (prostate-specific antigen (PSA) ≥ 0.2 ng/mL) is used as a surrogate for cancer control.

Results and limitations: The mean age \pm standard deviation (SD) was 60.2 ± 6 years. Median PSA level was 7.0 (interquartile range (IQR) 5.3–9.6) ng/mL. The mean operating time \pm SD was 186 ± 49 mins. The complication rate was 15.75% comprising Clavien grade I–II and Clavien grade III complications in 10.5% and 5.25% of patients respectively.

The overall positive surgical margin rate was 19.2% with T2 and T3 positive margin rates of 9.6% and 42.3% respectively. The biochemical recurrence-free survival was 86.6% at a median follow-up of 22 (IQR = 15–30) months. At 12 months follow-up, 91.4% of patients were pad-free or used a security liner. Of those men previously potent (defined as Sexual Health Inventory for Men [SHIM] score ≥ 21) who underwent nerve-sparing RALP, 62% were potent at 12 months.

Conclusions: The safety and feasibility of RALP has already been established. Our initial experience with this procedure shows promising short-term outcomes.

© 2008 European Association of Urology. Published by Elsevier B.V. All rights reserved.

^{*} Corresponding author. Department of Urology, Royal Melbourne Hospital, Grattan Street, Parkville, Victoria 3052, Australia. Tel. +61 (0)3 9429 9555; Fax: +61 (0)3 9429 9759.
E-mail address: decmurphy@doctors.net.uk (D.G. Murphy).

1. Introduction

Tens of thousands of patients with localised prostate cancer have now undergone robotic-assisted laparoscopic radical prostatectomy (RALP) using the da Vinci[®] surgical system (Intuitive Surgical, Sunnyvale, CA). The feasibility and safety of this procedure have been well established since its introduction in 2000, and reports from high-volume centres suggest excellent short and medium-term functional and oncological outcomes for patients undergoing this procedure [1,2].

We installed the first da Vinci[®] surgical system in Australia in 2003, and to date have performed over 800 RALPs. Four hundred of our patients have completed a minimum of one year follow-up. Our technique has evolved over five years as our experience has developed. We report and demonstrate our technique as it currently stands. The peri-operative characteristics and short-term functional and oncological outcomes for this cohort are also reported.

2. Patients and methods

2.1. Patient selection & preparation

Following a period of training which included visits to experienced centres and da Vinci[®] dry and cadaveric laboratory training, two experienced open surgeons with no previous laparoscopic experience started our RALP programme in December 2003. A mentor was present for the first few cases. All patients with primary localised prostate cancer considered suitable for open radical prostatectomy were offered RALP.

2.2. Surgical technique

2.2.1. Patient positioning and port placement

The patient is placed in low lithotomy position and secured to the table taking care to protect all pressure points. Less than 30° of Trendelenburg tilt is required (Fig. 1). A six-port transperitoneal approach is used (Fig. 2).

2.2.2. Robotic instruments

Five Endo Wrist[®] (Intuitive Surgical, Sunnyvale, CA) robotic instruments are used: monopolar curved shears; Maryland bipolar grasper; Prograsp grasper and large needle drivers (x2).

2.2.3. Development of the extra-peritoneal space

The 0° telescope is used initially. The median umbilical ligaments are incised and the space of Retzius is entered. The symphysis pubis is identified and the extraperitoneal space is developed laterally until the vasa are identified. Once the bladder has been adequately mobilized, the dome is grasped using the Prograsp and the fourth arm is used to maintain cranial retraction.

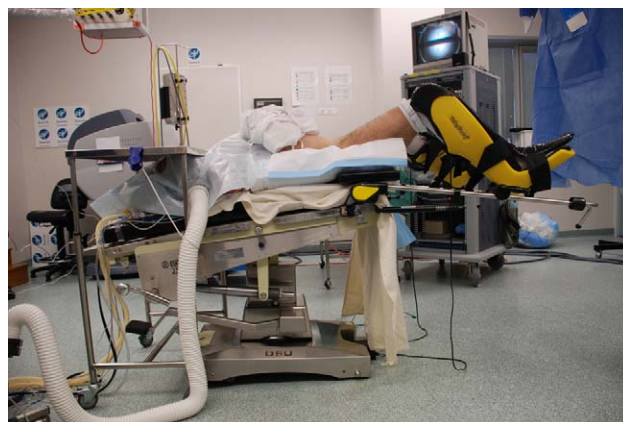

Fig. 1 – The patient is secured to the table and placed in low lithotomy position with 30° Trendelenburg tilt. The hips and knees are flexed to 30° and 40° respectively with slight leg abduction. A table is placed over the patient's head to protect the head and airway.

2.2.4. Incision of the endopelvic fascia (EPF) and ligation of dorsal venous complex (DVC)

The EPF is divided at the base of the prostate using cold scissors and the levator ani fibres are swept laterally. Dissection proceeds towards the apex using bipolar cautery to deal with small vessels. The puboprostatic ligaments are divided and the notch between DVC and urethra is exposed. The DVC is ligated using 0 Vicryl[™] (Ethicon Pty Ltd, North Ryde, NSW, Australia) on a CT-1 needle (Fig. 3). This suture is then anchored through the pubis to elevate the ligated DVC.

2.2.5. Bladder neck transection

The 30° down-angle telescope is attached. Identification of the bladder neck is aided by moving the catheter balloon and noting

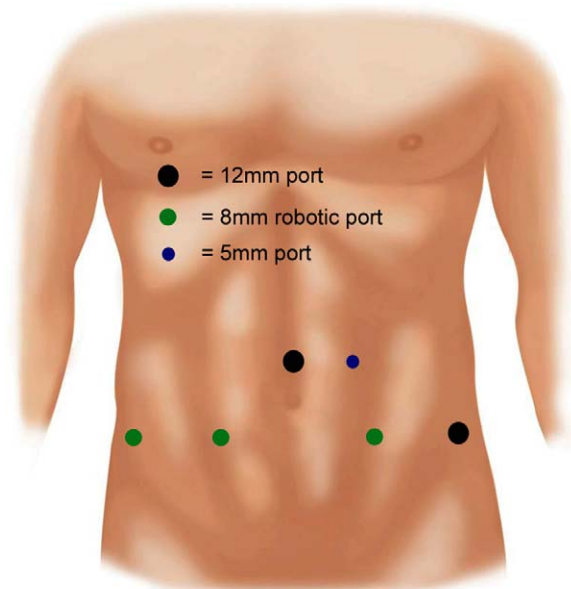


Fig. 2 – A six-port transperitoneal technique is used.

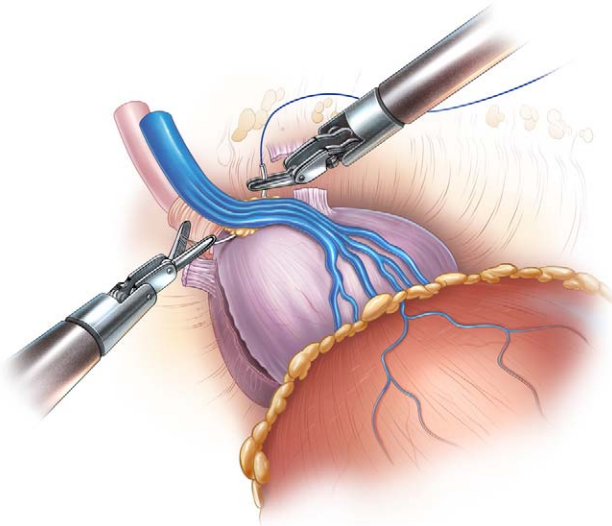


Fig. 3 – The dorsal venous complex is ligated using 1/0 Vicryl®.

where the overlying vesical fat ceases at the prostato-vesical junction. The anterior bladder neck is divided using the monopolar scissors until the catheter is identified within the bladder (Fig. 4). The balloon is deflated and the catheter delivered into the operative field. An Endo Close™ trocar site closure device (Tyco Healthcare, Lane Cove, NSW, Australia) is used to percutaneously pass a 1/0 nylon suture through the eye of the catheter. By withdrawing the suture through the abdominal wall this provides efficient anterior retraction of the prostate.

The full thickness of the posterior bladder neck is divided in the midline using monopolar cautery (Fig. 5). The posterior lip of the bladder neck can then be retracted cranially by the assistant allowing the console surgeon to develop the plane leading to the vasa and seminal vesicles (SVs). Lateral

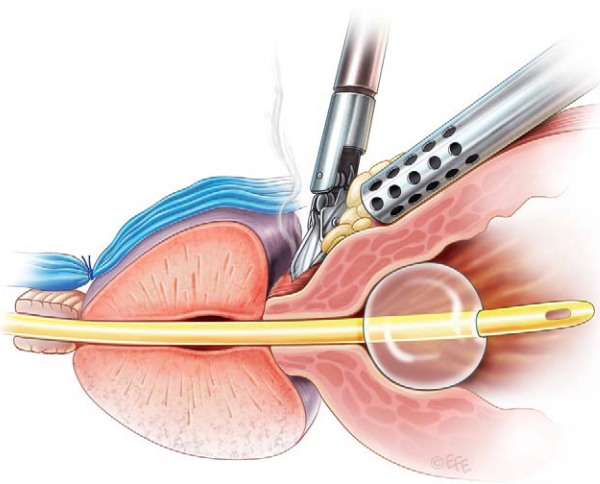


Fig. 4 – The anterior bladder neck is divided using monopolar cautery.

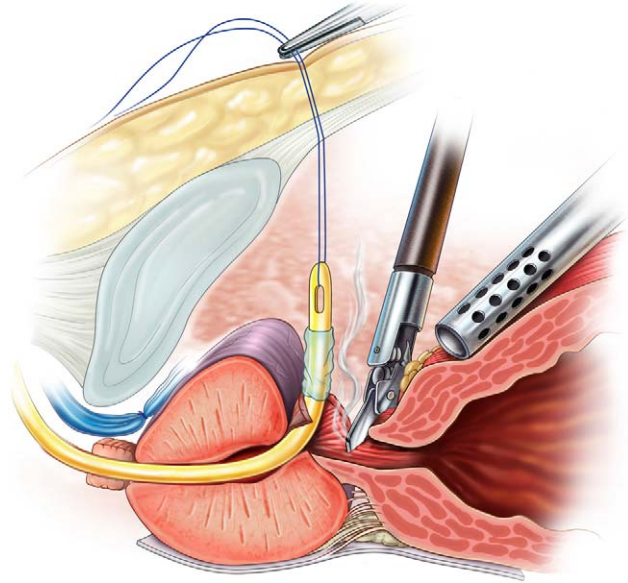


Fig. 5 – The posterior bladder neck is divided in the midline. The vasa and seminal vesicles are identified once the longitudinal fibres of the detrusor fascia have been divided.

bladder attachments are divided allowing the bladder to fall away.

2.2.6. Posterior dissection

The fascia overlying the vas is incised allowing adequate retraction of the posterior structures. The vas is mobilised and divided. The assistant or fourth arm is used to retract the distal end of vas anteriorly while the SV is dissected free. Vessels at the tip of the SV are ligated using metal clips (Fig. 6). Once both SVs have been fully mobilized to the base, they are retracted anteriorly by the assistant, thereby tenting up the posterior

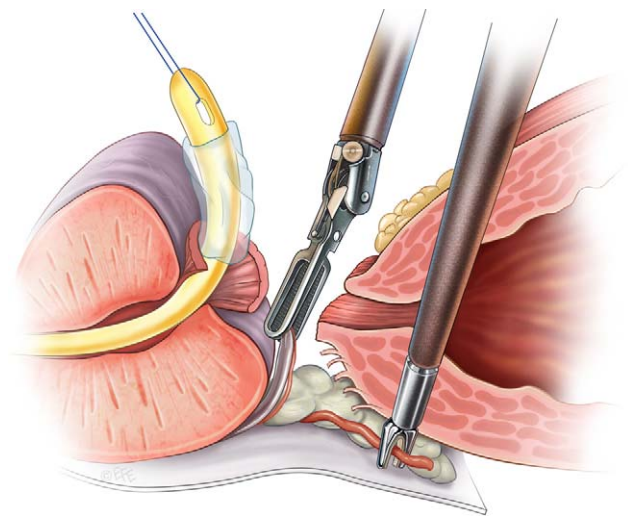


Fig. 6 – The left seminal vesicle is dissected free. Titanium clips are used to ligate small vessels at the tip of the vesicle.

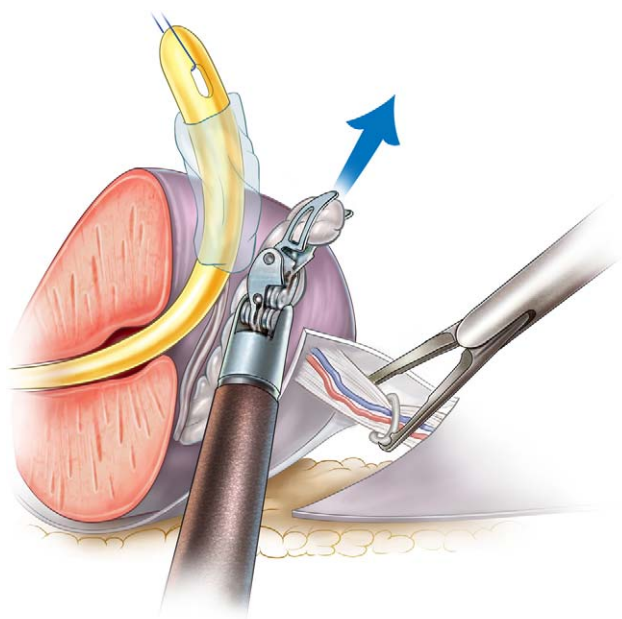


Fig. 7 – Hem-o-lok® clips are used to ligate the prostatic pedicle.

layer of Denonvillier's fascia. This layer is incised close to the base of the SVs and the peri-rectal fat is identified. Blunt dissection of this posterior space allows a safe plane to develop between prostate and rectum and also exposes the lateral pedicles of the prostate.

2.2.7. Ligation of prostatic pedicle

The pedicle is thinned out using blunt dissection to allow its ligation using Hem-o-lok® (Weck Closure Systems, Research Triangle Park, NC, USA) clips (Fig. 7). The clips are placed close to the prostate to avoid damage to the neurovascular bundle. Division of the pedicle frees the postero-lateral aspect of the prostate and exposes the groove between the NVB laterally, rectum posteriorly, and prostate supero-medially.

2.2.8. Nerve-sparing dissection

A nerve-sparing dissection (unilateral or bilateral) is offered to previously potent patients (Sexual Health Inventory for Men (SHIM) score ≥ 21) without palpable disease or radiological evidence of extracapsular extension. The NVB is mobilized using sharp dissection from base to apex of prostate (Fig. 8). The interfascial plane in the postero-lateral groove is developed using a cautery-free technique until the apex and urethra are visualized.

2.2.9. Apical dissection and transection of urethra

Contralateral traction is maintained by the assistant or fourth arm, and the 30° telescope is rotated to allow an excellent view of the apical dissection as the NVB is carefully swept away. The ligated DVC is then divided using the monopolar scissor. The lateral pillars are sharply incised and the anterior wall of the urethra is divided using cold scissors (Fig. 9). The catheter is withdrawn to expose the posterior wall of urethra which is

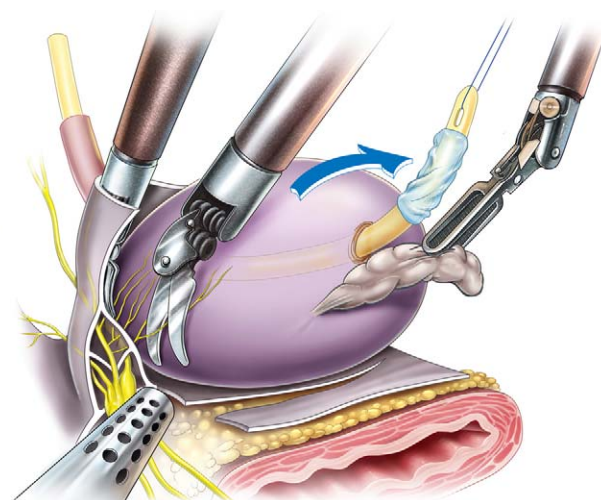


Fig. 8 – The neurovascular bundle is dissected free using sharp dissection in an athermal manner. The standard technique is used to release the bundle from the postero-lateral groove.

divided. The resected prostate is entrapped in a laparoscopic retrieval bag for later removal.

2.2.10. Pelvic lymph node dissection

Dissection of the obturator and external iliac lymph nodes is offered to patients with high-risk disease.

2.2.11. Urethrovessical anastomosis

A continuous suture is used for the anastomosis [3]. One dyed and one undyed 16 cm 2/0 Monocryl™ (Ethicon PTY Ltd, North Ryde, NSW, Australia) sutures on 27 mm CT-2 needles are tied together with ten throws. The undyed and dyed sutures are passed through the bladder neck from outside-in at 5 and 7 o'clock respectively (Fig. 10). The 0° telescope is attached to improve the view of the urethra. Each suture is passed through the urethra twice and bladder neck three times before the bladder is parachuted down by

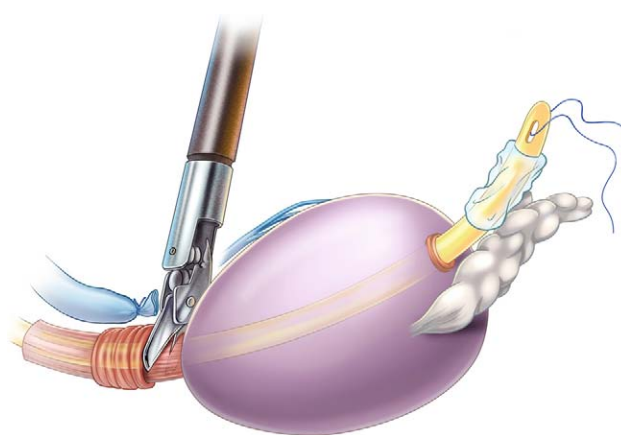


Fig. 9 – The DVC and urethra are divided to completely free the prostate and SVs.

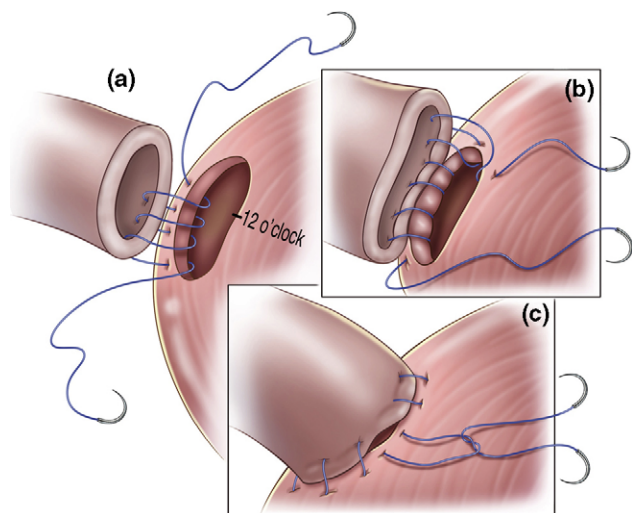


Fig. 10 – Continuous urethro-vesical anastomosis: (a) the posterior wall of anastomosis is completed by starting each suture at the 5 and 7 o'clock position and passing through the bladder neck three times and the urethra twice; (b) the posterior and right wall of anastomosis completed using the undyed arm of the Monocryl® suture, the left wall is completed once the right suture has reached the 12 o'clock position; (c) sutures reach 12 o'clock position and are tied to complete the watertight anastomosis.

pulling directly upwards on both sutures. The undyed suture continues in an anti-clockwise manner while the dyed suture continues clockwise until the 12 o'clock position is reached. Both sides of the urethra are tied together at the 12 o'clock position. The bladder is filled with normal saline to test the anastomosis.

2.2.12. Specimen retrieval and closure

A Yeates drain is placed through a lateral port site. The specimen is retrieved through the midline camera port following undocking of the robot. The fascia is closed with 1/0 Vicryl™ and the skin incisions closed with surgical skin adhesive.

2.3. Post-operative care

Patients are allowed clear fluids 4–6 h post-operatively and progress to light diet thereafter. They are encouraged to mobilize from 6 h post-operatively. The drain is removed within 24 h and patients are discharged 24–48 h post-operatively. The catheter is removed on post-operative day 7–10.

2.4. Histopathological analysis

The radical prostate specimens are fixed in buffered formalin for 24 hours. The margins are coated with different inks to define the anterior, right and left posterior compartments. The prostate is sectioned in three to four mm transverse sections. The apical and bladder neck sections are then sagittally

sectioned. The whole prostate is embedded. A computerised whole mount specimen is recreated. A positive pathological margin is defined as the presence of malignant cells transected by the inked margin.

2.5. Definitions, data collection and analysis

Complications were categorised using the Clavien system [4]. Patients were considered continent by the use of no pads or use of a liner for security. Potency was defined by a SHIM score ≥ 21 . Biochemical failure was defined as a PSA ≥ 0.2 ng/mL. International Continence Society and Sexual Health Inventory for Men (SHIM) questionnaires were filled pre-operatively and at 3, 6, 12, 18, 24 months and yearly thereafter. Prostate specific antigen (PSA) levels were recorded at the same intervals.

A prospective database was maintained by a data manager and research nurse. We reviewed this database to examine the demographics, peri-operative data, complications, oncological and functional outcomes of 400 consecutive patients who underwent RALP at our institution between December 2003 and August 2006.

The data was entered into an Excel™ (Microsoft, Redmond, WA) spreadsheet and analysed with an SPSS software package version 15 (SPSS Inc, Chicago, IL, USA).

3. Results

3.1. Perioperative parameters

From December 2003 to August 2006, 400 consecutive patients underwent RALP at our institution. Patient characteristics and peri-operative parameters are summarized in Table 1. The mean total operative time dropped below 200 min after 50 cases and dropped to a series mean of 186 min soon after (Fig. 11). Thirty-eight patients underwent pelvic lymph node dissection.

In total, 63 patients had complications (15.75%). Of these, 42 (10.5% of series) had Clavien grade I/II complications not requiring any surgical or radiological intervention. The 21 patients who had Clavien grade III complications include five patients who sustained a rectal injury (1.25% of series). Of these, three were identified and repaired intra-operatively without further sequelae. The remaining two required re-operation with temporary diverting colostomy. One patient was re-operated on due to bleeding and fifteen patients (3.75%) developed anastomotic stricture requiring dilatation. There were no peri-operative deaths.

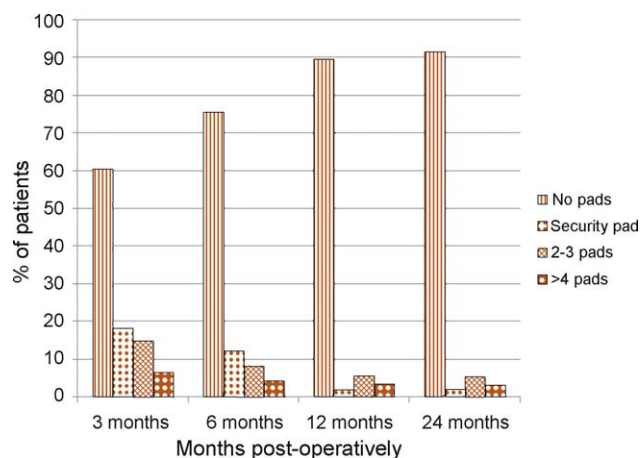
3.2. Pathological parameters

The final pathological results are summarized in Table 1. The proportion of patients with organ-confined prostate cancer was 70%. The overall,

Table 1 – Peri-operative characteristics (n = 400)

Parameter	Value
Mean age \pm SD (yr) (range)	60.2 \pm 6.0 (43–75)
Mean BMI \pm SD (kg/m ²) (range)	27.2 \pm 3.3 (20.2–39.8)
Clinical stage	
T1	279 (69.7%)
T2	111 (27.7%)
T3	10 (2.6%)
Median PSA (ng/mL) (interquartile range)	7.0 (5.3–9.6)
D'Amico risk category	
Low	146 (36.5%)
Intermediate	201 (50.25%)
High	53 (13.25%)
Mean total operative time \pm SD (min) (range)	186 \pm 49 (94–435)
Number of blood transfusions	10 (2.5%)
Conversion to open surgery	1 (0.25%)
Complication rate – overall	63 (15.75%)
Clavien I–II	42 (10.5%)
Clavien III	21 (5.25%)
Clavien IV	0
Clavien V	0
Final pathological outcome (%)	
T2a//b/c	70
T3a	25
T3b	4.75
T4	0.2
Positive surgical margins – overall (%)	19.2
T2	9.6
T3	42.3
Mean prostate weight \pm SD (g) (range)	48.9 \pm 20.2 (18–182)
Numbers undergoing PLND (positive for cancer)	38 (6)
Mean hospital stay \pm SD (d) (range)	3.1 \pm 1.4 (1–12)
Mean duration of catheterisation \pm SD (d) (range)	8.2 \pm 3.1 (4–33)

SD = standard deviation; BMI = Body Mass Index; PSA = prostate-specific antigen; PLND = pelvic lymph node dissection.

**Fig. 12 – Return of continence post-RALP.**

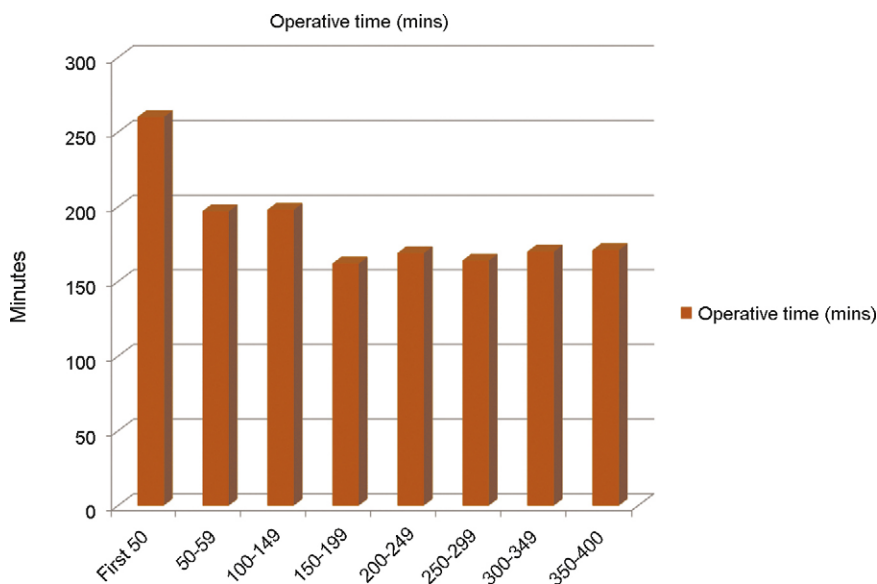
pT2 and pT3 positive surgical margin (PSM) rates were 19.2%, 9.6% and 42.3% respectively. Six of the 38 patients (15.8%) who underwent PLND had metastatic prostate cancer on histopathological analysis.

3.3. Functional outcomes

Follow-up data is available for 395 of 400 patients (98.7%).

3.3.1. Return of continence

At 12 months post-operatively, 361 patients (91.4%) were socially dry, as defined by the use of no pads (n = 354) or use of a liner (n = 7) for security or occasional stress incontinence (Fig. 12). This

**Fig. 11 – Total operative time grouped in consecutive groups of 50.**

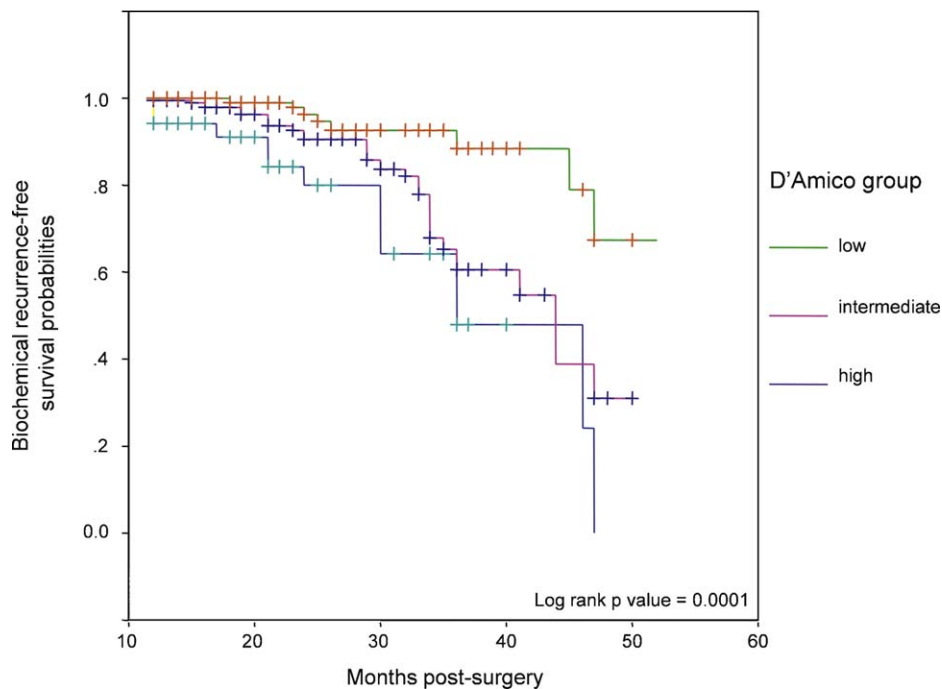


Fig. 13 – Biochemical recurrence-free survival in D'Amico low, intermediate and high-risk groups.

proportion reached 94.7% at 36 months of follow-up. The number of patients requiring more than four pads per day at 12 months was 13 (3.3%). One patient underwent insertion of an artificial urinary sphincter.

3.3.2. Return of potency

Of 248 previously potent men, 232 underwent nerve-sparing RALP. Of these, 162 (69.9%) underwent bilateral nerve-sparing. At 12 months follow-up, 144 (62%) of previously potent patients who under-

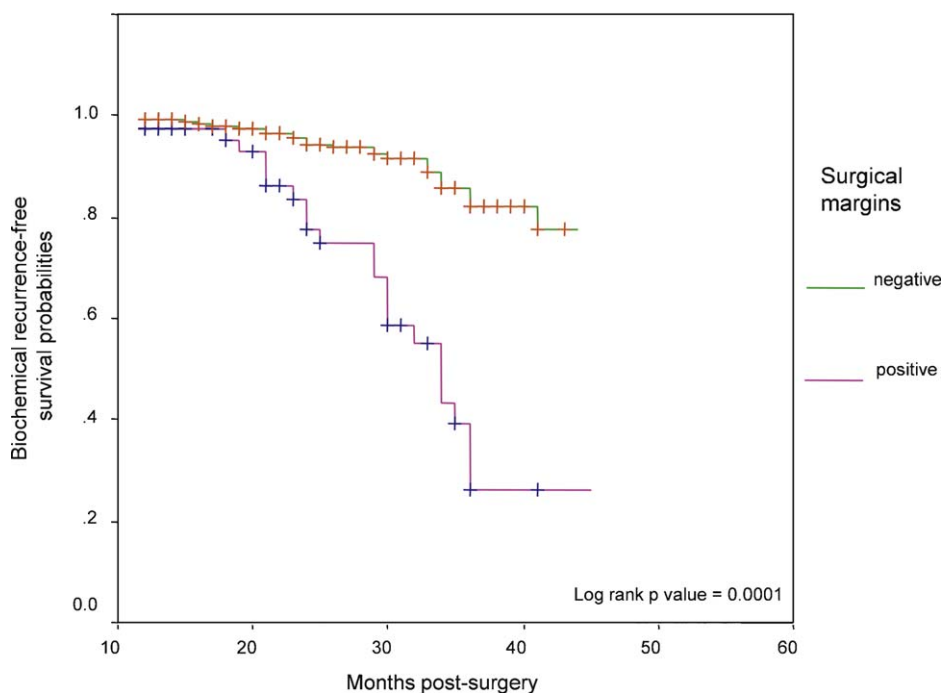


Fig. 14 – Biochemical recurrence-free survival in patients with and without positive surgical margins.

went nerve-sparing RALP were potent, usually with the assistance of phosphodiesterase-5 inhibitors.

3.4. Biochemical recurrence

Complete follow-up oncological data was available on 395 of our first 400 patients (98.7%). All of these patients had a minimum of 12 months follow-up (median = 22 mo; interquartile range = 15–30 mo). There were four deaths in the series, two of which were related to metastatic prostate cancer and two of which were related to other cancers. Fifty-three patients had a biochemical recurrence (13.4%). The cumulative five-year biochemical recurrence-free survival (BCRFS) was 74%. When analyzing the survival curves using the log rank test, there were significant differences in BCRFS rates for patients with low, intermediate and high-risk prostate cancer (Fig. 13), and patients with positive and negative surgical margins (Fig. 14). Thirty-eight patients (9.6%) received adjuvant radiation and/or androgen ablation treatment.

4. Discussion

The penetration of RALP into the radical prostatectomy market in the past five years has been remarkable. Though there is no level I evidence to support its use over conventional laparoscopic radical prostatectomy (LRP) or open radical prostatectomy, reports from centres of excellence suggest RALP is a low morbidity procedure producing PSM rates of 9.3–20.9% and potency and continence rates of 70–80% and 90.2–95% respectively [1,2,5,6]. Whilst debate continues about the evidence-base and cost-effectiveness of RALP, it appears that in countries where health economic conditions allow, most urologists (and patients) are opting for the robotic-assisted approach despite the lack of level I evidence.

Our technique has evolved over five years as our experience has developed. We used a vascular stapler on the DVC for the first few cases before opting for suture ligation. An anterior suspension stitch lifts the DVC off the urethra and facilitates easier placement of the anterior anastomotic sutures. It may also stabilise the anastomosis allowing an earlier return to continence [7]. The Endo Close™ device offers an efficient mechanism for achieving anterior retraction of the prostate.

The Clavien III complications in our series include five patients who sustained rectal injuries. Four of these were in the first 200 cases. Also, of the 15 patients who developed anastomotic stricture requiring dilatation, ten of these were in the first 200

cases with a lower rate of significant complications in the second half of this series.

The most notable change in our technique was the introduction of Hem-o-lok® clips to secure the vascular pedicle which occurred at case number 322. The avoidance of any cautery from this point onwards undoubtedly contributes to an improvement in potency outcomes [8] and this is our preferred approach for nerve-sparing radical prostatectomy. Sixty-two percent of previously potent patients in our series were potent at 12 months follow-up. The large majority of these pre-dated the introduction of Hem-o-lok clips® to our series and we have seen further improvement in our potency rates since that time. We prefer the standard approach for nerve-sparing RALP as described above, as opposed to the high-lateral release or “Veil” technique [9]. Though there are nerves present in the lateral fascia of the prostate, these nerves likely innervate the prostate directly rather than the cavernosal spaces and consequently have no proven impact on erectile function [10]. Initial enthusiasm for the “Veil” technique after potency claims of 97% [11] has been tempered by failure to reproduce these results using a similar technique [12]. Further cadaveric studies are underway to aid our understanding of the complex neuroanatomy of this area.

The introduction of terms such as “socially dry” and “security liner” renders the comparison of continence outcomes somewhat difficult. We have used these definitions here as they have been used by the largest published series [1,13] and by review articles on this topic [14]. At 12 months follow-up, 91.4% of patients were considered continent including 7 patients (1.8%) who continued to use a security liner.

The overall PSM rate in this series is 19.2% with a rate of 9.6% for T2 tumours. This compares favourably with other contemporaneous LRP and RALP series [2,5,6,12,15]. Of note, the proportion of patients with palpable disease (30.3%) and intermediate or high risk disease (64%) is considerably higher in this series than in series from high-volume North American centres [13], reflecting demographic differences related to PSA screening.

The senior author compared his previous 102 cases of open radical prostatectomy with his first 102 cases of RALP and noted a decrease in overall PSMs from 27% to 14% [16].

The overall cumulative five-year survival for this series is 74%. With a similar length of follow-up in a large cohort, Menon et al reported five-year actuarial BCRFS of 84% [1]. However, the proportion of patients in D’Amico low, intermediate and high risk

groups was 69.1%, 22.7% and 8.2% respectively. In our series, the corresponding proportions in low, intermediate and high risk groups were 36.5%, 50.25% and 13.25% respectively, reflecting some differences in case selection. Also, our series has a minimum follow-up of 12 months, inevitably leading to a higher BCRFS rate.

5. Conclusions

The safety and feasibility of RALP has already been established. This paper adds to the evidence of good short-term oncological outcomes for patients undergoing RALP for localised prostate cancer. The technique of RALP continues to evolve which may lead to further improvements in oncological and functional outcomes.

Author contributions: Declan G. Murphy had full access to all the data in the study and takes responsibility for the integrity of the data and the accuracy of the data analysis.

Study concept and design: Murphy and Costello.

Acquisition of data: Kerger, Crowe, Murphy.

Analysis and interpretation of data: Murphy.

Drafting of the manuscript: Murphy.

Critical revision of the manuscript for important intellectual content: Costello and Peters.

Statistical analysis: Murphy.

Obtaining funding: None.

Administrative, technical, or material support: None.

Supervision: Costello.

Other (specify): None.

Financial disclosures: I certify that all conflicts of interest, including specific financial interests and relationships and affiliations relevant to the subject matter or materials discussed in the manuscript (eg, employment/affiliation, grants or funding, consultancies, honoraria, stock ownership or options, expert testimony, royalties, or patents filed, received, or pending), are the following: None.

Funding/Support and role of the sponsor: Declan Murphy is supported by the Ellison-Cliffe Fellowship of the Royal Society of Medicine, the Prostate UK Travelling Fellowship, and the Ethicon Fellowship of the Royal College of Surgeons, Ireland. We are grateful to Niall Corcoran for assistance with statistical analysis and to Dr Levent Efe for assistance with illustrations.

Appendix A. Supplementary data

The Surgery in Motion video accompanying this article can be found in the online version, at [doi:10.1016/j.eururo.2008.12.035](https://doi.org/10.1016/j.eururo.2008.12.035) and via www.europeanurology.com. Subscribers to the printed journal will find the Surgery in Motion DVD enclosed.

References

- [1] Badani KK, Kaul S, Menon M. Evolution of robotic radical prostatectomy: assessment after 2766 procedures. *Cancer* 2007;110:1951–8.
- [2] Patel VR, Palmer KJ, Coughlin G, Samavedi S. Robotic-Assisted Laparoscopic Radical Prostatectomy: Perioperative Outcomes of 1500 Cases. *J Endourol* 2008;22:2299–306.
- [3] Van Velthoven RF, Ahlering TE, Peltier A, Skarecky DW, Clayman RV. Technique for laparoscopic running urethrovesical anastomosis: the single knot method. *Urology* 2003;61:699–702.
- [4] Dindo D, Demartines N, Clavien PA. Classification of surgical complications: a new proposal with evaluation in a cohort of 6336 patients and results of a survey. *Ann Surg* 2004;240:205–13.
- [5] Mottrie A, Van Migem P, De Naeyer G, Schattenman P, Carpentier P, Fonteyne E. Robot-assisted laparoscopic radical prostatectomy: oncologic and functional results of 184 cases. *Eur Urol* 2007;52:746–51.
- [6] Zorn KC, Gofrit ON, Orvieto MA, Mikhail AA, Zagaja GP, Shalhav AL. Robotic-assisted laparoscopic prostatectomy: functional and pathologic outcomes with interfascial nerve preservation. *Eur Urol* 2007;51:755–63.
- [7] Tewari A, Jhaveri J, Rao S, et al. Total reconstruction of the vesico-urethral junction. *BJU Int* 2008;101:871–7.
- [8] Ahlering TE, Eichel L, Skarecky D. Evaluation of Long-Term Thermal Injury Using Cautery During Nerve Sparing Robotic Prostatectomy. *Urology* 2008.
- [9] Kaul S, Bhandari A, Hemal A, et al. Robotic radical prostatectomy with preservation of the prostatic fascia: a feasibility study. *Urology* 2005;66:1261–5.
- [10] Costello AJ, Brooks M, Cole OJ. Anatomical studies of the neurovascular bundle and cavernosal nerves. *BJU Int* 2004;94:1071–6.
- [11] Menon M, Kaul S, Bhandari A, et al. Potency following robotic radical prostatectomy: a questionnaire based analysis of outcomes after conventional nerve sparing and prostatic fascia sparing techniques. *J Urol* 2005;174:2291–6, discussion.
- [12] Chabert CC, Merrilees DA, Neill MG, Eden CG. Curtain dissection of the lateral prostatic fascia and potency after laparoscopic radical prostatectomy: a veil of mystery. *BJU Int* 2008;101:1285–8.
- [13] Menon M, Shrivastava A, Kaul S, et al. Vattikuti Institute prostatectomy: contemporary technique and analysis of results. *Eur Urol* 2007;51:648–58.
- [14] Ficarra V, Cavalleri S, Novara G, Aragona M, Artibani W. Evidence from robot-assisted laparoscopic radical prostatectomy: a systematic review. *Eur Urol* 2007;51:45–56.
- [15] Stolzenburg JU, Rabenalt R, Do M, et al. Endoscopic extraperitoneal radical prostatectomy: the University of Leipzig experience of 1,300 cases. *World J Urol* 2007;25:45–51.
- [16] O'malley PJ, Van AS, Bouchier-Hayes DM, Crowe H, Costello AJ. Robotic radical prostatectomy in Australia: initial experience. *World J Urol* 2006;24:165–70.